Hand Surgery and Rehabilitation 41 (2022) 675–680

Available online at
ScienceDirect
www.sciencedirect.com

Elsevier Masson France
EM|consulte
www.em-consulte.com

Original article

Nerve regeneration conduit from inverted human umbilical cord vessel in the treatment of proper palmar digital nerve sections

Conduit de régénération nerveuse dérivé de vaisseau de cordon ombilical humain retourné dans le traitement de sections de nerfs digitaux palmaires propres

L. Ardouin [a], F.-A. Lecoq [a], F. Verstreken [b], B. Vanmierlo [c], L. Erhard [d], V. Locquet [d], L. Barnouin [e,*], J. Bosc [e], L. Obert [f]

[a] *Institut de la Main Nantes-Atlantique, Elsan Santé Atlantique, AV Claude Bernard, 44800 Saint Herblain, France*
[b] *AZ Monica, Florent Pauwelslei 1, 2100 Antwerp, Belgium*
[c] *AZ Delta, Deltalaan 1, 8800 Roeselare, Belgium*
[d] *Institut Chirurgical de la Main et du Membre Supérieur, 17 Av. Condorcet, 69100 Villeurbanne, France*
[e] *Tissue Bank of France (TBF), 6 rue d'Italie, 69780 Mions, France*
[f] *CHU de Besançon Hôpital Jean Minjoz, 3 Bd. Alexandre Fleming, 25000 Besançon, France*

ARTICLE INFO

Article history:
Received 22 July 2022
Received in revised form 22 September 2022
Accepted 26 September 2022
Available online 6 October 2022

Keywords:
Nerve conduit
Inverted umbilical cord vessel
Peripheral nerve repair
Hand microsurgery

ABSTRACT

Treatment of digital nerve injuries, particularly in case of a gap, is challenging. Recovery of finger sensitivity is often incomplete and can impair personal and occupational activity. The need for better nerve regeneration has given rise to alternative treatments such as nerve conduits. This study aimed to evaluate the safety and efficacy of a conduit of freeze-dried inverted human umbilical cord vessel for regeneration in digital nerve section. Twenty-three patients with a mean nerve gap of 6.11 mm (range 2–30 mm and static 2-point discrimination (s2PD) > 15 mm underwent surgical repair of digital nerve section using a nerve regeneration conduit. The primary endpoint was recovery of sensitivity after conduit implantation. Secondary endpoints comprised progression of pain, functional symptoms, pressure threshold, hand-specific symptoms and disabilities, and restored innervation. Mean follow-up was 10.1 ± 4.1 months (range 1–14 months). Sensitivity recovered progressively in the months following implantation. There was a mean decrease of 8.54 mm in s2PD between baseline and last follow-up ($p < 0.001$). Complete innervation recovered in 83.3% of cases at last follow-up. Pressure threshold and hand-related quality of life improved significantly and symptoms due to nerve sectioning (pain, cold intolerance, hypoesthesia, hyperesthesia) resolved almost completely. There were no safety issues related to the nerve conduit. These results indicate that freeze-dried inverted human umbilical vessels can be a safe and effective option as conduit for digital nerve regeneration.

Mots-clés:
Conduit nerveux
Vaisseau ombilical inversé
Réparation des nerfs périphériques
Microchirurgie de la main

RÉSUMÉ

Le traitement des lésions des nerfs digitaux, en particulier celles avec perte de substance (PDS), reste un défi. La récupération de la sensibilité des doigts est souvent incomplète et peut interférer avec les activités personnelles et professionnelles. La nécessité d'une meilleure régénération a donné lieu au développement de traitements alternatifs tels que les conduits nerveux. Cette étude visait à évaluer la sécurité et l'efficacité d'un vaisseau ombilical retourné et lyophilisé d'origine humaine utilisé comme conduit de régénération pour les sections de nerfs digitaux. Au total, 23 patients présentant une PDS moyenne de 6,11 mm (intervalle 2–30 mm) et une valeur de discrimination de 2 points statiques (s2PD) > 15 mm ont été traités chirurgicalement avec le conduit de régénération nerveuse. Le critère d'évaluation principal était la récupération de la sensibilité après l'implantation du conduit. Les critères d'évaluation secondaires comprenaient les changements relatifs à la douleur, les symptômes

* Corresponding author.
E-mail address: laurence.barnouin@tbf-lab.com (L. Barnouin).

https://doi.org/10.1016/j.hansur.2022.09.239

fonctionnels, le seuil de pression, les symptômes et incapacités liés à la section nerveuse ainsi que la régénération de l'innervation. La durée moyenne de suivi était de 10,1 ± 4,1 mois (intervalle 1–14 mois). La sensibilité a été récupérée progressivement dans les mois suivant l'implantation. Une diminution moyenne de 8,54 mm du s2PD a été observée entre l'inclusion et la fin de l'étude ($p < 0,001$). L'innervation a été complètement récupérée dans 83.3% des cas à la dernière visite. Le seuil de pression et la capacité de la main dans les activités quotidiennes se sont améliorés de manière significative, tandis que les symptômes dus à la section nerveuse (douleur, intolérance au froid, hypoesthésie, hyperesthésie) ont diminué à presque zéro. Aucun événement lié à la sécurité du conduit nerveux n'a été signalé. Ces résultats indiquent que les vaisseaux ombilicaux humains lyophilisés et retournés peuvent être une option sûre et efficace pour la régénération des nerfs digitaux.

Introduction

Peripheral nerve transection in the hand is a common occurrence, with challenging major sensory and motor consequences. When digital nerves are injured, recovery of finger sensory function is often incomplete. Strategies adopted for surgical repair depend largely on the size and type of nerve injury. Direct tension-free end-to-end surgical repair is the gold-standard for reconstruction after complete transection with <5 mm gap, whereas autologous nerve graft (ANG) is used for longer gaps [1–3]. Although clearly advantageous in terms of biocompatibility, ANG has major drawbacks, including limited availability of donor nerves, harvesting-related complications and donor-site morbidity, mismatch with the size of the injured nerve, potential permanent loss of nerve function, and possible occurrence of painful neuroma. These limitations have given rise to alternative strategies for larger injuries, with the development of synthetic or biological tools used as nerve guidance conduits or scaffolds [3–12], since it was established that interposing a graft between proximal and distal nerve stumps ensured better regeneration [1,11–14]. However, synthetic conduits present various disadvantages: they are prone to degradation by inflammation or require secondary surgery to remove them after nerve regeneration, and in some cases rigidity can lead to extrusion. To optimize nerve regeneration, nerve scaffolds need chemical and physical properties that mimic their physiological environment. Non-autologous tissues (nerve allograft, biopolymers such as collagen) or autologous tissues (tendon, muscle, amniotic membranes, umbilical cord (UC) vessels, veins, arteries) show better surgical outcomes [1,14–23]. Since nerve allograft induces immune reactions, devitalized products are used in combination with collagen conduits: nerve-conduit type products [23–25]. For digital nerves, outcomes are similar to those obtained with autologous vein grafts (AVGs), effective in bridging small nerve gaps and improving directional axon regrowth [5,8,11,15]. However, there are concerns related to graft size and lumen collapse in > 5 mm gaps. Therefore, AVG is used only for digital nerve lacerations with little or no gap. To improve nerve repair, conduits combining vein tract with fresh skeletal muscle fibers have been developed [10,26–29]. The rationale of the muscle-in-vein (MIV) approach is that muscle prevents vein collapse, while the vein wall provides a natural tube in which axon elongation can occur without spread. All these devices have similar performances in terms of nerve regeneration [30], with good sensory and motor recovery [19,31,32]. However, outcomes are worse for >10 mm gaps, when treatment is delayed due to infection-related complications, or when the wound is associated with tendon injury [22].

Since perinatal tissues display low immunogenicity, they have been used in regenerative medicine as allogenic material for more than a century [33]. UC is a tube-like structure enclosing one vein and two arteries buried within a protective glycoprotein-rich extracellular matrix called Wharton's jelly (WJ).

Vessels enclosed in the human UC have been turned inside-out and filled with WJ to form a conduit. In some respects, this resembles an MIV conduit, known to be well tolerated and effective as a 3D scaffold for sciatic nerve regeneration in rats [34]. The aim of the present study was to evaluate the efficacy and safety of a freeze-dried inverted human umbilical cord vessel (iHUCV) in the treatment of severed digital nerves.

Patients and methods

Patients

Patients aged 18–65 years with 2−20 mm hand nerve gap were included in the month following injury or accident, and could be included during emergency treatment. Patients with underlying motor or sensory disorder, disease compromising healing, vascular disease leading to reduced blood flow or impaired microvascularization, or drug or alcohol addiction were excluded.

Study design

This phase II prospective open-label non-comparative clinical trial was conducted in four centers. The protocol and informed consent forms (including one dedicated to emergency settings) were reviewed and approved by the institutional review boards of the study centers. All included patients underwent surgical repair of peripheral nerve injury by iHUCV (NerVFIX®; TBF, Mions, France). Baseline characteristics were established at inclusion or at the 2-week postoperative consultation for patients included and treated in emergency. Clinical tolerance and sensory and motor function were assessed at 1 months, 3 months, 6 months and 12 months after nerve repair.

Treatment

The nerve regeneration conduit was made of an allogeneic UC vessel (vein or artery) turned inside-out [34]. The outer surface was the vascular wall, the inner lumen surface was residual WJ rich in physiological proteoglycans. Safety was maximized during manufacturing according to the European directives for the quality and safety of human tissues and cells. Deep cleaning, devitalization and viral inactivation was ensured by chemical treatment; conservation used freeze-drying, and final product safety was ensured by sterilization. The iHUCV was supplied as a ready-to-use dehydrated sterile tube, 0.5–1.5 mm thick, flexible but firm, and available in various lengths and diameters.

All patients were treated with the following procedure. The nerve gap was measured after debridement, wound cleaning and recutting of severed nerve ends. The length and inner diameter of the iHUCV were selected according to the size of the nerve gap and the nature of the wound. The iHUCV was implanted as nerve

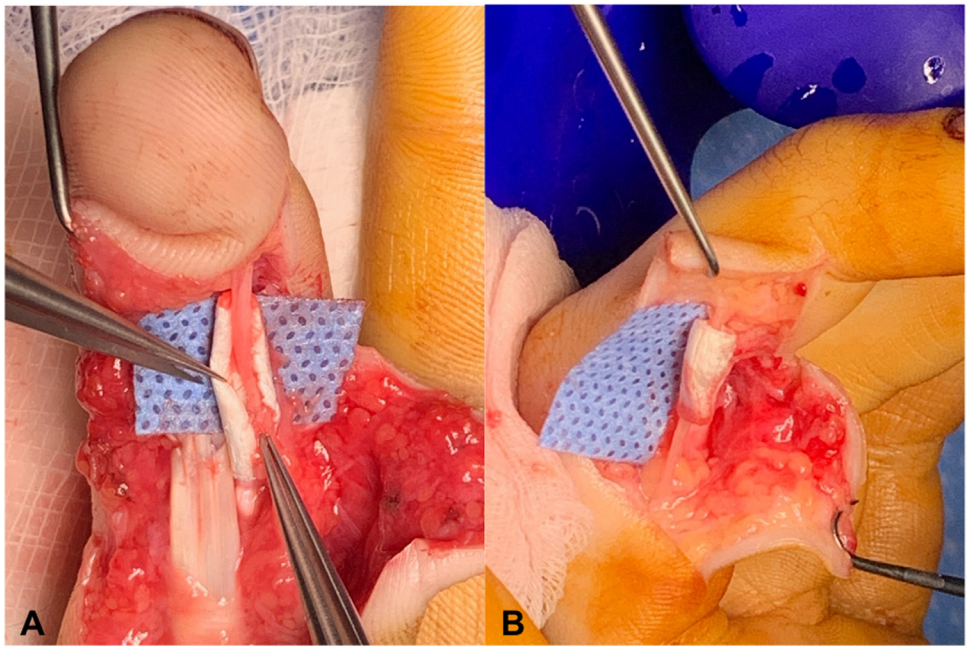

Fig. 1. Intraoperative photographs, before suturing, of the iHUCV implanted as nerve wrapping (A) or nerve conduit (B).

wrapping or nerve conduit (Fig. 1). Wrapping was used when nerve ends could be sutured: the iHUCV was opened longitudinally and wrapped around the sutured nerve, and an external running suture was performed to rebuild the conduit. Nerve conduit was used when nerve ends could not be directly sutured due to the gap; the two nerve ends were inserted in the conduit and stabilized by epineural suture. The iHUCV was rehydrated with physiological serum after implantation.

Clinical evaluation

The primary efficacy endpoint was recovery of sensitivity 12 months after nerve regeneration conduit implantation. Sensory recovery was evaluated using the British Medical Research Council (MRC) score modified by Mackinnon and Dellon [35]. Due to nerve sectioning, baseline static 2-point discrimination (s2PD) was greater than 15 mm. Grade S3+ (s2PD = 7–15 mm) indicates recovery of pain and touch sensitivity, with disappearance of overresponse. Grade S4 (s2PD $<$ 7 mm) indicates complete recovery.

Secondary efficacy endpoints comprised progression of pain, functional symptoms, pressure threshold in the repaired nerve area, hand-specific symptoms and disabilities, and restored innervation. Pain was rated by the patients from 0 (no pain) to 10 (worst imaginable pain) on a visual analog scale. Cold intolerance, hyperesthesia and numbness were graded by the patients on a scale from 0 (no sensation) to 4 (major sensation). Pressure threshold was evaluated by the Semmes-Weinstein monofilament (SWM) test [36]; interpretation is presented in Table 1. Symptoms and disabilities of the hand were self-reported by the patients using the QuickDASH questionnaire [37]; final QuickDASH score, calculated from 11 items, ranges from 0 (no disability) to 100 (worst possible disability). The Hoffmann-Tinel (HT) sign [38] was used as an indication of peripheral nerve fiber regeneration. It was assessed by distal to proximal percussion over the path of the nerve, and was considered positive when the patient reported a tingling sensation along the nerve path. Absence of HT sign indicated complete nerve regeneration. All efficacy evaluations were made at baseline and at months 1, 3, 6 and 12. Adverse events were monitored and reported throughout the study.

Statistical analysis

Statistical analyses were performed using R 4.0.2 software (R Core Team, Vienna, Austria). Normal distribution was analyzed on Shapiro-Wilk test. A paired Student t-test was used to compare measurements between groups for variables with normal distribution; otherwise, a Wilcoxon rank-sum test was used. Rejection of the null hypothesis was defined as $\alpha < 0.05$ (two-tailed).

Results

Study population

Twenty-five patients for 26 nerve sections were included and treated. Two nerve sections in two patients were excluded from efficacy analysis as the main criterion (s2PD) was not evaluated at inclusion time and during follow-up. Demographic and surgical techniques are shown in Table 2. Six of the 23 analyzed patients did not meet all the inclusion and exclusion criteria. For 3 patients, the time between injury and surgery was >1 month (92, 137 and

Table 1
Semmes-Weinstein monofilament (SWM) interpretation scale.

SWM score	1	2	3	4	5
SWM number	2.83	3.61	4.31	4.56	6.65
Target force (g)	0.07	0.2	2	4	200
Interpretation	Normal superficial sensation	Loss of superficial sensation, protective sensation intact	Loss of protective sensation, deep pressure sensation intact	Total loss of pressure sensation	Residual sensation

Table 2
Demographic and surgical data.

Number of analyzed patients	23
Number of analyzed nerve sections	24
Gender (% female)	26%
Mean age (range) (years)	38 (19–65)
Right hand involvement	37.5%
Mean length (in mm) of nerve gap at inclusion (range)	6.11 (2–30)
Nerve lesion location	
Thumb	4
Index finger	7
Middle finger	5
Ring finger	1
Little finger	7
Time between injury and surgery (in days) (range)	25 (0–264)
Implantation technique (% conduit / % wrap)	43%/57%

264 days, respectively). One patient had a nerve gap of 30 mm at inclusion. One had Raynaud syndrome with peripheral cold intolerance, and 1 had chronic alcoholism with signs of peripheral neuropathy.

The schedule of the study was impacted by the COVID-19 pandemic. Some patients were not able to come to all follow-up visits. Last follow-up was at a mean 10.1 months (range 1–14 months; Table 3).

Efficacy

Table 4 summarizes the efficacy results. s2PD decreased progressively between follow-up consultations. A significant mean decrease of 8.54 mm was observed between baseline and last follow-up ($p < 0.001$, two-tailed paired t-test). There was complete recovery (s2PD < 7 mm) for 13 nerve sections at last follow-up (54.17%). On the 10-point scale, pain decreased significantly by 4.10 points ($p < 0.001$). All functional symptoms showed significant decrease. On the 4-point scale, cold intolerance, hyperesthesia and numbness decreased by 1.12 ($p = 0.012$), 1.02 ($p = 0.008$) and 2.46 points ($p < 0.001$), respectively. The pressure threshold of the repaired nerve area improved significantly ($p < 0.001$). Globally, patients went from having only residual sensation at inclusion (SWM = 4.78 ± 0.56) to restored pressure sensation (SWM = 2.72 ± 0.97). HT sign was absent in 20 of the 24 digits (83.33%) at last follow-up. The global patient-reported score for symptoms and disabilities of the hand was 36.49 ± 25.15 points at baseline and decreased to 7.20 ± 13.05 points at last follow-up ($p < 0.001$).

Table 4
Outcome assessments.

Variable	N	Mean ± SD		Significance test (p-value)
		Baseline	Last visit	
s2PD (mm)	24	16.00 ± 0.00	7.46 ± 3.08	<0.001
Pain	24	4.56 ± 1.97	0.46 ± 1.06	<0.001
Functional symptoms:				
Cold sensation	24	1.46 ± 1.74	0.34 ± 0.76	0.012
Hyperesthesia	24	1.43 ± 1.57	0.41 ± 0.84	0.008
Numbness	24	2.91 ± 1.19	0.45 ± 0.94	<0.001
SWM (threshold)	18[a]	4.78 ± 0.56	2.72 ± 0.97	<0.001

[a] SWM test not done at baseline for 6 nerve sections.

Safety

One patient (4.3%) developed cubital tunnel syndrome, 1 (4.3%) developed early local infection, and 1 (4.3%) developed complex regional pain syndrome (CRPS). These events had no relation with the graft, and all 3 patients showed sensory recovery.

Discussion

Treatment of nerve transection, particularly with gap, historically used AVG as a tubular junction [15]. Using vessels as nerve conduit is an alternative to ANG for the repair of severed hand nerves [2], described for over 30 years [15] and implemented

Table 3
Nerve repair patient data.

Case n°	Gender	Age (yrs.)	Finger injured	Gap length (mm)	Final follow-up (months)	Final s2DP (mm)	Final SWM target force (g)	Final HT sign	Final QuickDASH	Comments
F1-01	M	35	LLF	4	12	7	2	no	0.0	
F1-02	F	45	LT	4	13	12	2	yes	4.5	Chronic alcoholism with signs of peripheral neuropathy
F1-03	M	33	LMF	2	13	8	0.07	no	0.0	
F1-04	F	41	LMF	3	12	6	0.07	no	0.0	
F1-05	M	65	RLF	13	12	6	2	no	2.3	
F1-06	M	44	LIF	5	12	6	2	no	4.5	
F1-07	M	51	LT	3	12	6	0.2	no	0.0	
F1-08	M	22	LLF	3	10	8	0.2	no	0.0	
F1-09	F	28	LT	2	12	6	0.2	no	13.6	Raynaud syndrome with peripheral cold sensation
F1-10	M	19	LLF	NR	11	4	0.2	no	0.0	
			LRF	NR		6	0.2	no		
F1-11	M	19	LMF	3	6	10	4	no	2.3	
F1-12	M	24	RLF	4	1	14	200	no	56.8	
F2-01	F	38	RT	8	13	6	2	no	0.0	
F2-02	F	48	LLF	10	7	6	2	no	2.3	
F2-03	M	40	RIF	3	9	6	2	no	0.0	
B1-01	M	60	RIF	7	12	8	2	no	22.7	
B1-02	M	23	LIF	30	12	10	2	no	0.0	
B1-03	M	52	RLF	5	1	16	4	no	18.2	
B2-02	M	48	LMF	NR	12	4	0.2	yes	4.5	
B2-03	M	24	RIF	3	1	8	0.2	yes	20.5	
B2-04	F	30	LIF	4	14	4	2	yes	13.6	
B2-05	M	42	RMF	NR	13	4	4	no	0.0	
B2-06	M	43	RIF	NR	12	8	0.2	no	0.0	

LIF: left index finger; *LLF*: left little finger; *LMF*: left middle finger; *LRF*: left ring finger; *LT*: left thumb; *NR*: not reported; *RIF*: right index finger; *RLF*: right little finger; *RMF*: right middle finger; *RT*: right thumb.

mainly to overcome the morbidity associated with donor sensory nerve harvesting. In addition to being widely available, veins have structural advantages as a source of conduit material [5,14,18,21], the 3 layers of the laminin/collagen-rich basal membrane providing a more adequate microenvironment for directional axon regrowth [17]. Vein walls are also resilient enough to act as a barrier against scar ingrowth, and their permeability allows nutrient diffusion. However, there are limitations related to the size of the graft (particularly for larger median, ulnar and radial nerves) and to lumen collapse for >5 mm gaps, impeding nerve regeneration [14–16]. Therefore, AVGs are used only in digital nerve lacerations with little or no gap. To limit collapse, one strategy consists in filling veins with muscle (MIV conduit) [10,26]. The usefulness of fresh muscle fibers is that, in addition to preventing the vein from collapsing, the muscle's basal lamina enhances the proliferation and migratory properties of resident Schwann cells [10,11,23,30], while the vein walls prevent dispersion of muscle fibers and scar tissue invasion. Thus, MIV conduits are a good alternative to traditional ANGs for nerve gaps exceeding the graft length limit typical of other types of tubulization [9,26–29]. There are a few high-quality randomized controlled studies and systematic reviews on the use of AVG and MIV as nerve regeneration conduits for the treatment of digital nerve transection, reporting promising functional recovery compared with direct nerve repair or ANG [5,15,16,18,20–22,26–28,39,40]. Chui et al. [15] published a prospective clinical evaluation of AVG as nerve conduit for ≤3 cm distal sensory nerve defects, compared to direct repair and ANG. At last follow-up (mean: 27 months [6;72]), s2PD for direct repair, ANG and AVG was 7.40 ± 1.54, 9.00 ± 1.00 and 11.10 ± 3.40 mm, respectively, indicating superiority of direct nerve repair in palmar digital nerve section. Significant symptom relief and satisfactory recovery of sensory function were systematically observed with all three techniques. Twenty years later, Rinker et al. [18] published a prospective randomized study comparing synthetic woven polyglycolic acid conduits versus AVG for the reconstruction of > 4 mm digital nerve gaps (mean: 10 mm [4;25]). Mean s2PD at 12 months was comparable for both (7.5 ± 1.9 and 7.6 ± 2.6 mm, respectively), indicating similar sensory recovery. MIV was effectively employed as a nerve guide for secondary nerve reconstruction of segmental nerve injuries in Marcoccio et al.'s study [27], with a mean gap of 22 mm [10;34]. s2PD and QuickDASH scores were assessed. At ≥ 18 months' follow-up, 66.7% of the reconstructed nerves were classified as excellent or good on the modified MRC scale (S3+, S4) and mean QuickDASH score was 22.5. A few years later, Manoli et al. [28] conducted a retrospective clinical trial comparing regeneration after reconstruction of 10–60 mm digital nerve injuries with MIV conduits, ANG or direct suture. No significant differences between repair techniques were found on s2PD and SWM tests up to 58 months' follow-up. The authors also emphasized that ANGs incur harvesting-related complications, with reduced sensitivity at the donor-site in 71.4% of cases, compared to only 7.1% with MIV conduits.

The iHUCV has tissue characteristics similar to an MIV graft. The structure needs to be inverted to make it more resistant to collapsing. Moreover, it provides a lumen free of venous valves, circumventing the disadvantage of AVG, which is prone to obstruct regenerating axons and to neuroma formation [2,14]. The final product is a porous structure composed of a vascular outer surface of endothelium (tunica intima), a smooth or double-smooth muscular layer (tunica media), and an inner valveless lumen surface filled with residual WJ [17,34]. The collagen-rich matrix and hyaluronic acid environment inside the chamber optimize nerve repair, allowing cellular sliding and directional axonal regrowth with remyelination, as demonstrated when used as a 3D scaffold for sciatic nerve regeneration in rats [34]. In addition to being widely available from UC donors, its biomaterial characteristics offer adequate mechanical properties, with sufficient flexibility and stability to protect the injured nerve area and prevent scarring, yet firm enough to preclude risk of collapse during nerve regeneration. Since its allogeneic/xenogeneic cellular antigens have been removed by decellularization, the iHUCV is fully biocompatible and resorbs progressively during nerve regeneration [33], avoiding long-term inflammation with no need for secondary surgery [5,13]. It is supplied freeze-dried and sterile, in various lengths and diameters (2–3 mm UC artery or 5–7 mm UC vein) easily adaptable to the nature and the size of the severed nerve: longitudinal or perpendicular cut, either to wrap the nerve or as a tubular conduit for ≤ 20 mm gaps.

The present findings indicate that iHUCV can help recovery of sensitivity in the 12 months following surgical nerve repair. At last follow-up, 95.8% of the reconstructed nerves were between S3+ and S4 on the modified MRC scale and recovery was complete (S4) in 54.17% of cases. The one reconstructed nerve that did not reach grade S3+ or S4 was the one followed for the shortest period (1 month). Mean s2PD at last follow-up was 7.46 ± 3.08 mm. Compared to other studies, sensitivity recovery was therefore comparable to that obtained with MIV [27,28] and superior to that with AVG [15,18]. In addition, all functional symptoms and pain progressively improved, with very few clinical signs of nerve section at last follow-up. Cold intolerance, hyperesthesia, numbness and pain decreased by 76.7%, 71.3%, 84.5% and 89.9%, respectively, between baseline and last follow-up. Signs of peripheral nerve fiber regeneration, defined by absence of HT sign, were observed in 83.3% of patients. Mean QuickDASH score was 7.20 ± 13.05 at last follow-up, indicating minimal disability of the hand. Those results are at least comparable to those reported with MIV in other studies [27,28].

In terms of vessel conduit safety, reported adverse events were not specifically related to the product, since they cannot be dissociated from trauma and surgery: local infection, healing issues such as wound inflammation or delayed haeling. Reports of graft failure or extrusion, neuroma formation and other complications are quite inconsistent. For MIV grafts, no adverse events were reported by Manoli et al. [28], while 2 painful neuromas (failure of gap repair) were reported by Marcoccio et al. [27]; in this phase II study, 3 events were reported by the investigators, none related to the iHUCV.

Conclusions

In this study, iHUCV devitalized allograft to repair severed digital nerves with ≤ 20 mm gaps provided excellent sensory and functional recovery. The iHUCV has the tissue characteristics of an MIV conduit and shows similar efficacy, with results superior to those reported for AVG. Moreover, it was well tolerated and no specific complications occurred. Thus, iHUCV is a promising alternative to conventional treatments for long peripheral nerve gaps, offering many of the advantages expected from a biological nerve conduit.

Conflict of interest

The authors declare the following financial or personal relationships that could be viewed as influencing the work reported in this paper:
L.B., Financial interests in the TBF company.
J.B., Employee of TBF company.
L.O., Consultant for TBF company.
The remaining authors have no conflicts of interest to disclose.

Author contributions

All authors attest that they meet the current International Committee of Medical Journal Editors (ICMJE) criteria for Authorship

Funding

This work did not receive any grant from funding agencies in the public, commercial or not-for-profit sectors.

Human and animal rights

The authors declare that the work described here was carried out in accordance with the Declaration of Helsinki of the World Medical Association revised in 2013 for experiments involving humans as well as in accordance with the EU Directive 2010/63/EU for animal experiments.

Informed consent and patient details

The authors declare that they obtained written informed consent from the patients included in the study and that this report does not contain any personal information that could lead to their identification.

Acknowledgments

The authors extend special thanks to all the staff of the centers involved in the study in France (Institut de la Main – Nantes Atlantique, Saint-Herblain; Institut Chirurgical de la Main et du Membre Supérieur, Villeurbanne) and Belgium (AZ Sint-Jan Brugge – Oostende AV, Brugge; AZ Monica, Antwerp). The authors are also grateful to Nathalie Baudry for assistance with manuscript preparation.

References

[1] Siemionow M, Brzezicki G. Current techniques and concepts in peripheral nerve repair. Int Rev Neurobiol 2009;87:141–72.
[2] Slutsky DJ. The management of digital nerve injuries. J Hand Surg Am 2014;39:1208–15.
[3] Tezcan AH. Peripheral nerve injury and current treatment strategies. In: Mauricio AC, editor. Peripheral nerve regeneration — from surgery to new therapeutic approaches including biomaterials and cell-based therapies development. Croatia: InTechOpen; 2017. p. 1–30.
[4] Belkas JS, Shoichet MS, Midha R. Peripheral nerve regeneration through guidance tubes. Neurol Res 2004;26:151–60.
[5] Battiston B, Geuna S, Ferrero M, Tos P. Nerve repair by means of tubulization: literature review and personal clinical experience comparing biological and synthetic conduits for sensory nerve repair. Microsurgery 2005;25:258–67.
[6] Nectow AR, Marra KG, Kaplan DL. Biomaterials for the development of peripheral nerve guidance conduits. Tissue Eng B Rev 2012;18:40–50.
[7] Griffin JW, Hogan MV, Chhabra AB, Deal DN. Peripheral nerve repair and reconstruction. J Bone Joint Surg Am 2013;95:2144–51.
[8] Konofaos P, Ver Halen JP. Nerve repair by means of tubulization: past, present, future. J Reconstr Microsurg 2013;29:149–64.
[9] Lin MY, Manzano G, Gupta R. Nerve allografts and conduits in peripheral nerve repair. Hand Clin 2013;29:331–48.
[10] De Stefano ME, Toni F, D'Orazi V, Ortensi A, Tata AM. Therapeutic approaches enhancing peripheral nerve regeneration. Adv Biosci Biotechnol 2013;4:53–60.
[11] Geuna S, Tos P, Titolo P, Ciclamini D, Beningo T, Battiston B. Update on nerve repair by biological tubulization. J Brachial Plex Peripher Nerve Inj 2014;9:3.
[12] Regas I, Loisel F, Haight H, Menu G, Obert L, Pluvy I. Functionalized nerve conduits for peripheral nerve regeneration: a literature review. Hand Surg Rehabil 2020;39:343–51.
[13] Muheremu A, Ao Q. Past, present and future of nerve conduits in the treatment of peripheral nerve injury. Biomed Res Int 2015;2015237507.
[14] Sabongi RG, Fernandes M, Gomes dos Santos JB. Peripheral nerve regeneration with conduits: use of vein tubes. Neural Regen Res 2015;10:529–33.
[15] Chiu DT, Strauch B. A prospective clinical evaluation of autologous vein grafts used as a nerve conduit for distal sensory nerve defect of 3 cm or less. Plast Reconstr Surg 1990;86:928–34.
[16] Meek MF, Coert JH. Clinical use of nerve conduits in peripheral-nerve repair: review of the literature. J Reconstr Microsurg 2002;18:97–109.
[17] Crouzier T, McClendon T, Tosun Z, McFetridge PS. Inverted human umbilical arteries with tunable wall thicknesses for nerve regeneration. J Biomed Mater Res A 2009;89:818–28.
[18] Rinker B, Liau JY. A prospective randomized study comparing woven polyglycolic acid and autogenous vein conduits for reconstruction of digital nerve gaps. J Hand Surg Am 2011;36:775–81.
[19] Brooks DN, Weber RV, Chao JD, Rinker BD, Zoldos J, Robichaux MR, et al. Processed nerve allografts for peripheral nerve reconstruction: a multicenter study of utilization and outcomes in sensory, mixed, and motor nerve reconstructions. Microsurgery 2012;32:1–14.
[20] Paprottka FJ, Wolf P, Harder Y, Kern Y, Paprottka PM, Machens HG, et al. Sensory recovery outcome after digital nerve repair in relation to different reconstructive techniques: meta-analysis and systematic review. Plast Surg Int 2013;2013704589.
[21] Ahmad I, Akhtar MS. Use of vein conduit and isolated nerve graft in peripheral nerve repair: a comparative study. Plast Surg Int 2014;2014587968.
[22] Braga Silva J, Marchese GM, Cauduro CG, Debiasi M. Nerve conduits for treating peripheral nerve injuries: a systematic literature review. Hand Surg Rehabil 2017;36:71–85.
[23] Han GH, Peng J, Liu P, Ding X, Wei S, Lu S, et al. Therapeutic strategies for peripheral nerve injury: decellularized nerve conduits and Schwann cell transplantation. Neural Regen Res 2019;14:1343–51.
[24] Hall S. Axonal regeneration through acellular muscle grafts. J Anat 1997;190:57–71.
[25] Gontika I, Katsimpoulas M, Antoniou E, Kostakis A, Stavropoulos-Giokas C, Michalopoulos E. Decellularized human umbilical artery used as nerve conduit. Bioengineering (Basel) 2018;5(4):100.
[26] Battiston B, Tos P, Cushway TR, Geuna S. Nerve repair by means of vein filled with muscle grafts: I. Clinical results. Microsurgery 2000;20:32–6.
[27] Marcoccio I, Vigasio A. Muscle-in-vein nerve guide for secondary reconstruction in digital nerve lesions. J Hand Surg Am 2010;35:1418–26.
[28] Manoli T, Schulz L, Stahl S, Jaminet P, Schaller HE. Evaluation of sensory recovery after reconstruction of digital nerves of the hand using muscle-in-vein conduits in comparison of nerve suture or nerve autografting. Microsurgery 2014;34:608–15.
[29] Kaushik AP, Hammert WC. Options for digital nerve gap. J Hand Surg Am 2015;40:141–4.
[30] Jessen KR, Mirsky R. The repair Schwann cell and its function in regenerating nerves. J Physiol 2016;594:3521–31.
[31] Mermans JF, Franssen BBGM, Serroyen J, Van der Hulst RRWJ. Digital nerve injuries: a review of predictors of sensory recovery after microsurgical digital nerve repair. Hand (N Y) 2012;7:233–41.
[32] Rbia N, Shin AY. The role of nerve graft substitutes in motor and mixed motor/sensory peripheral nerve injuries. J Hand Surg Am 2017;42:367–77.
[33] Arutyunyan I, Fatkhudinov T, Sukhikh G. Umbilical cord tissue cryopreservation: a short review. Stem Cell Res Ther 2018;9:236.
[34] Lecoq FA, Barnouin L, Ardouin L, Hartmann D, Obert L. Inverted human umbilical artery as a 3D scaffold for sciatic nerve regeneration in rats. Cell Tissue Bank 2022. Epub ahead of print.
[35] Novak CB, Kelly L, Mackinnon SE. Sensory recovery after median nerve grafting. J Hand Surg Am 1992;17:59–68.
[36] Bell-Krotoski JA. Light touch-deep pressure testing using Semmes-Weinstein monofilaments. In: Hunter JM, Schneider LH, Mackin EJ, Callahan AD, editors. Rehabilitation of the hand. 3rd ed., Mosby: St Louis; 1990. p. 585–93.
[37] Beaton DE, Wright JG, Katz JN, Upper Extremity Collaborative Group. Development of the QuickDASH: comparison of three item-reduction approaches. J Bone Joint Surg Am 2005;87:1038–46.
[38] Turgut AÇ, Tubbs RS, Turgut M. Paul Hoffmann (1884–1962 AD) and Jules Tinel (1879–1952 AD), and their legacy to neuroscience: the Hoffmann-Tinel sign. Childs Nerv Syst 2019;35:733–4.
[39] Weber RA, Breidenbach WC, Brown RE, Jabaley ME, Mass DP. A randomized prospective study of polyglycolic acid conduits for digital nerve reconstruction in humans. Plast Reconstr Surg 2000;106:1036–45.
[40] Rinkel WD, Huisstede BMA, van der Avoort DJC, Coert JH, Hovius SER. What is evidence based in the reconstruction of digital nerves? A systematic review. J Plast Reconstr Aesthet Surg 2013;66(2):151–64.